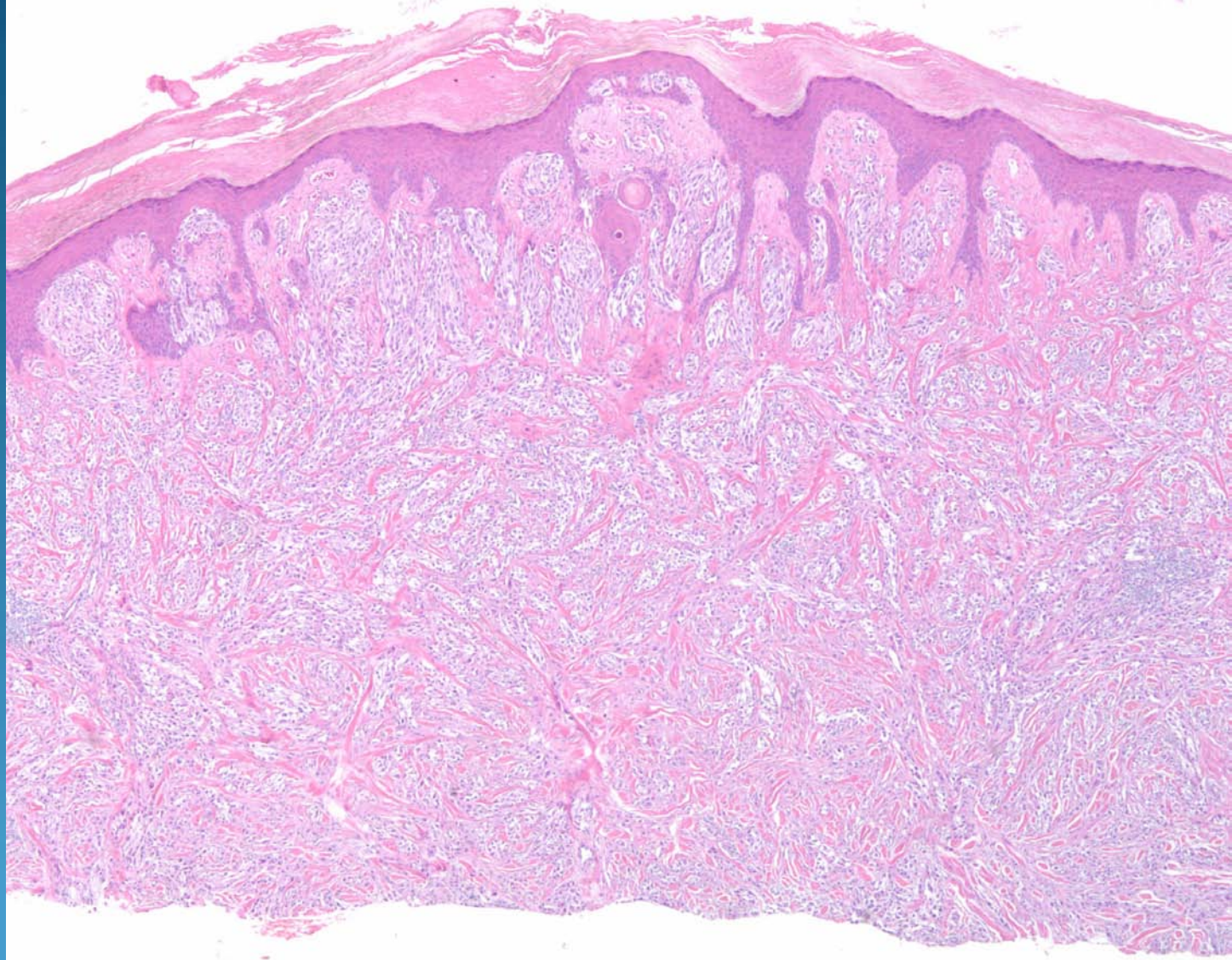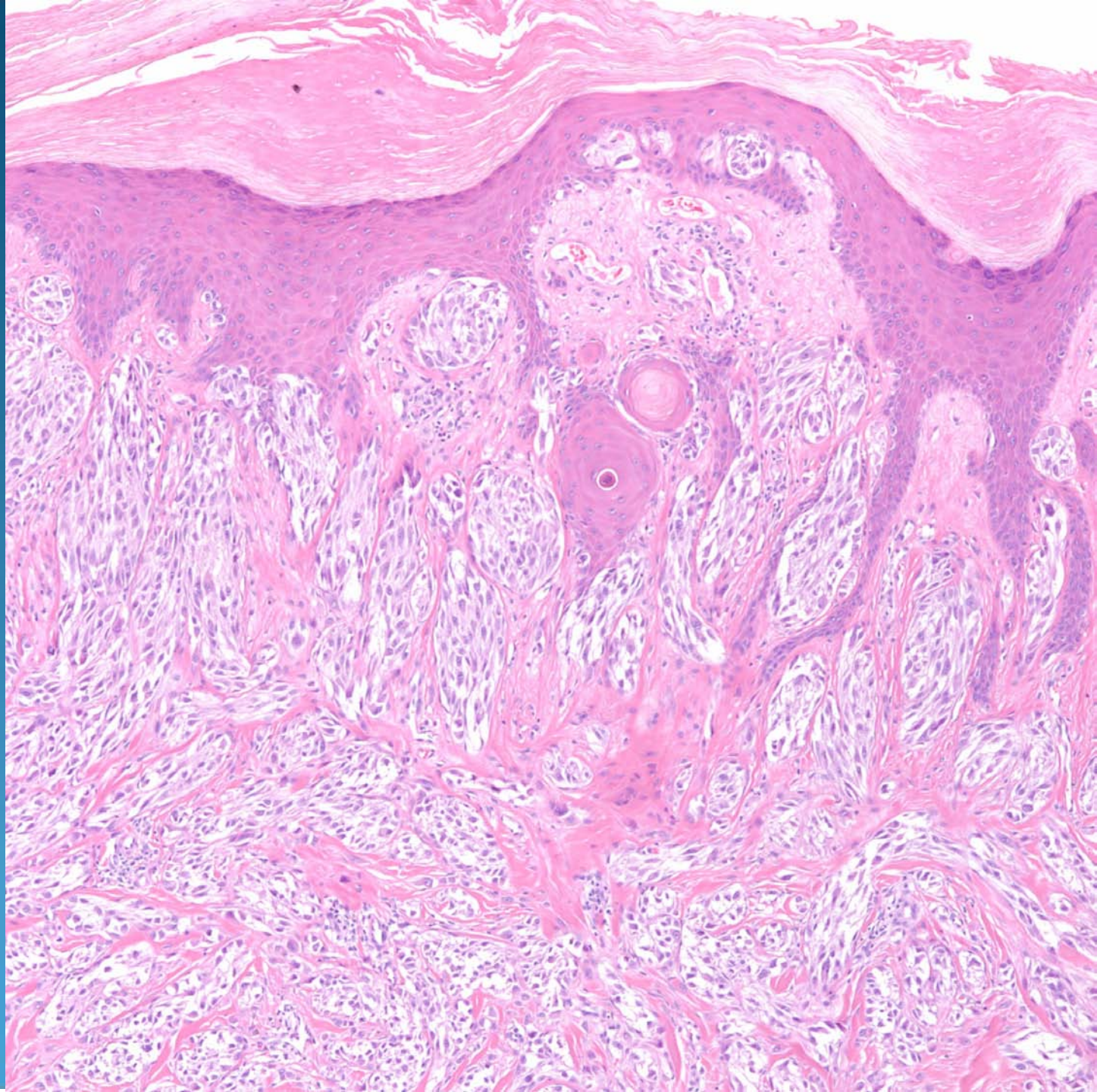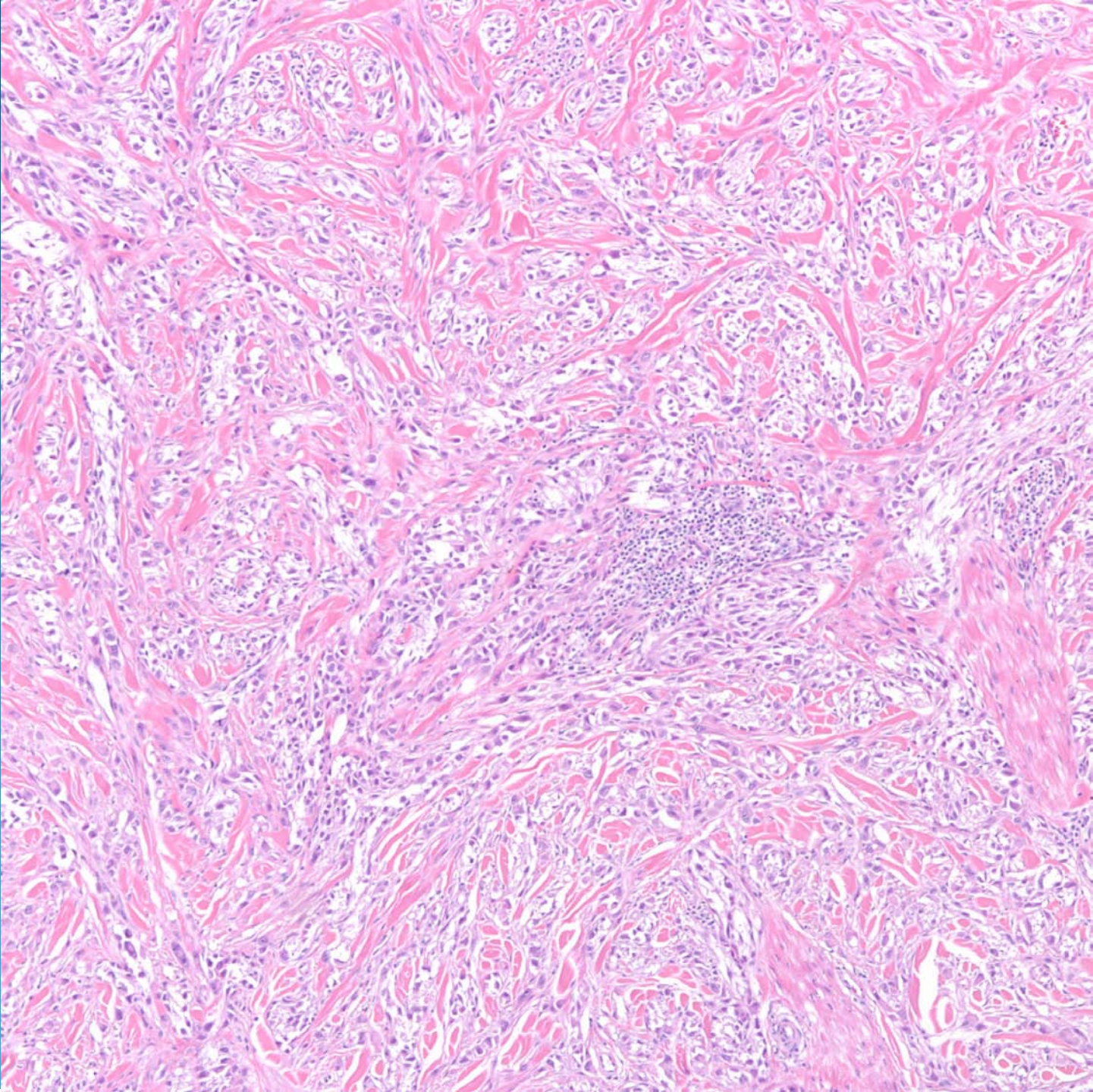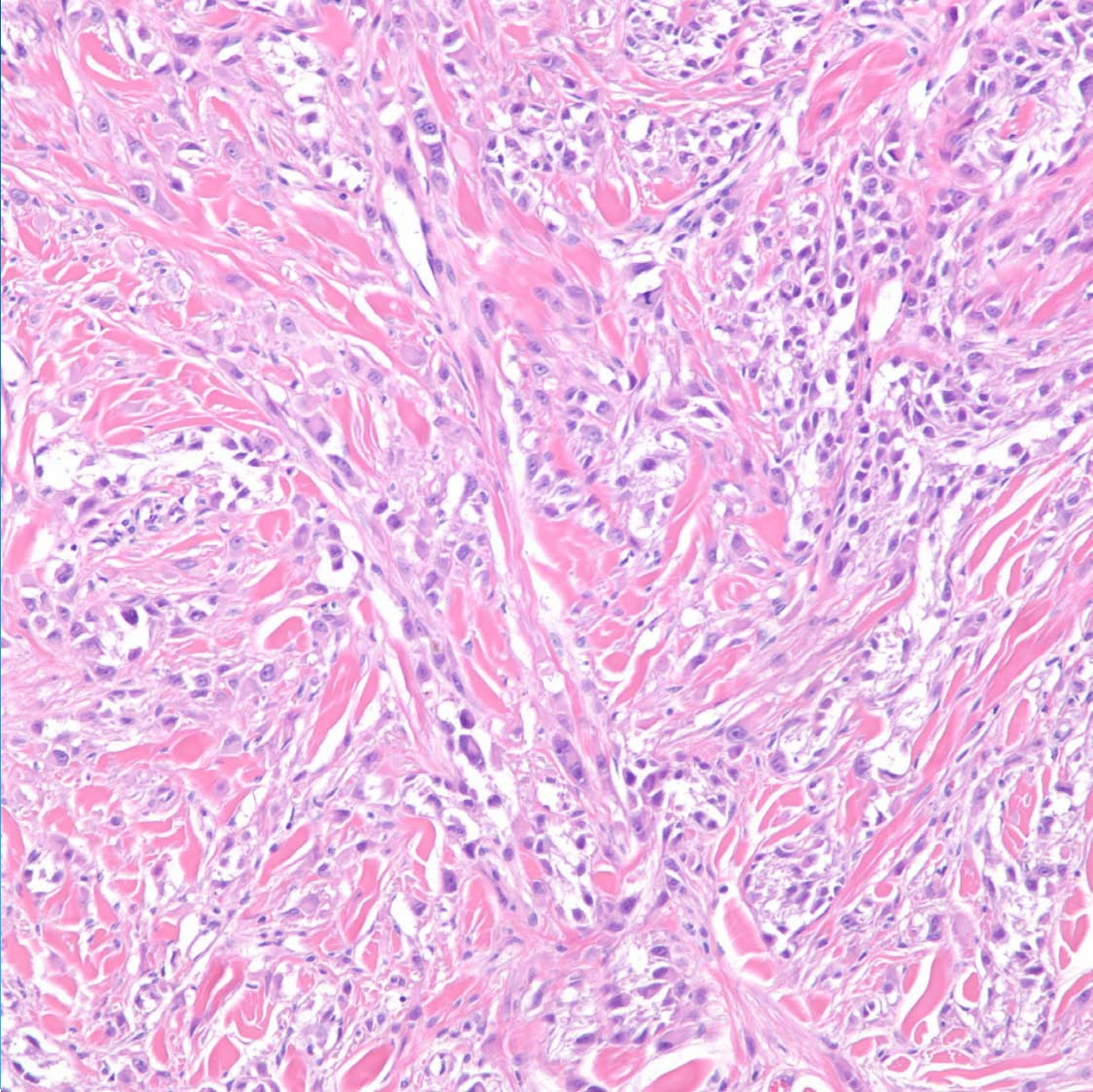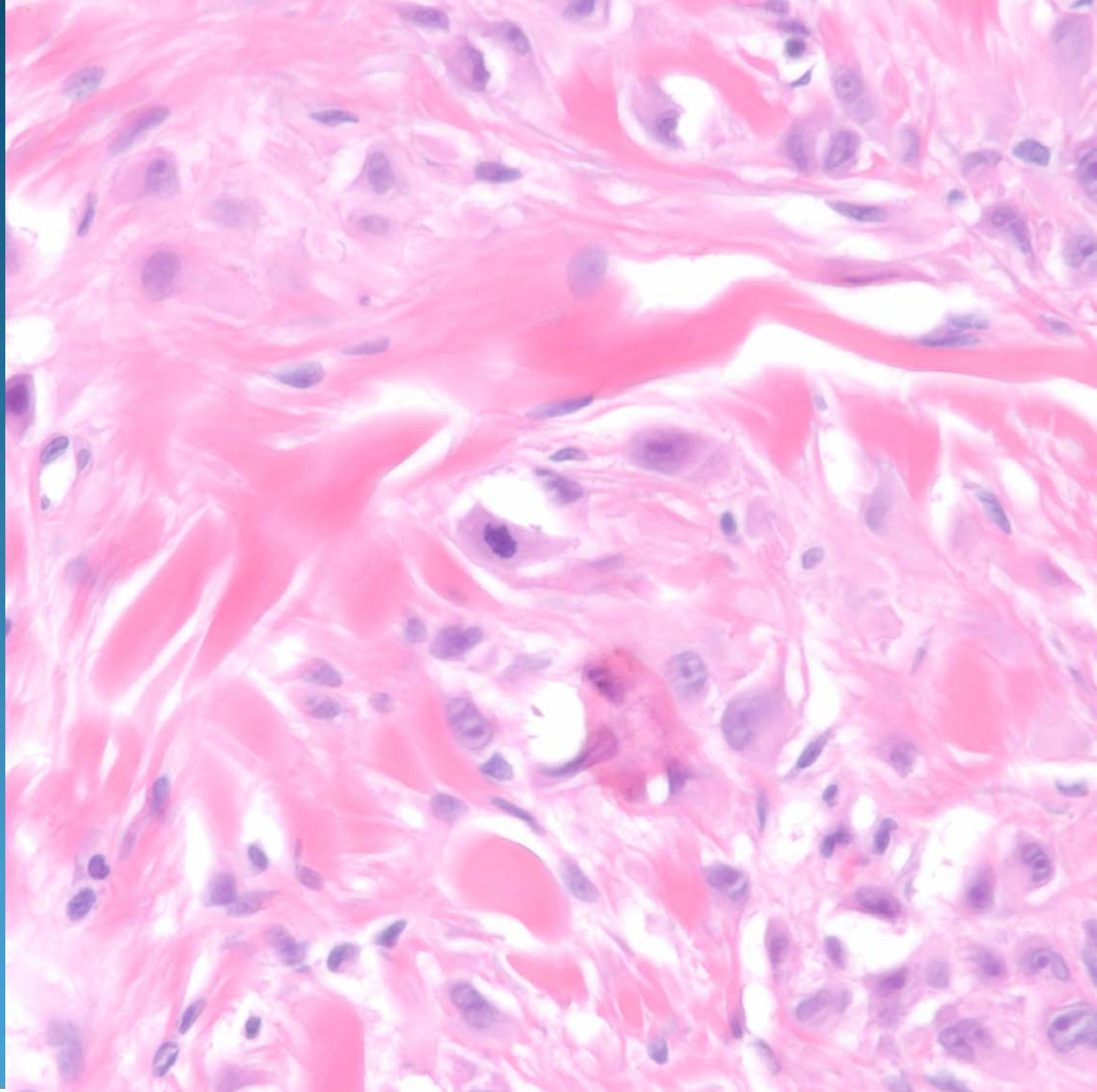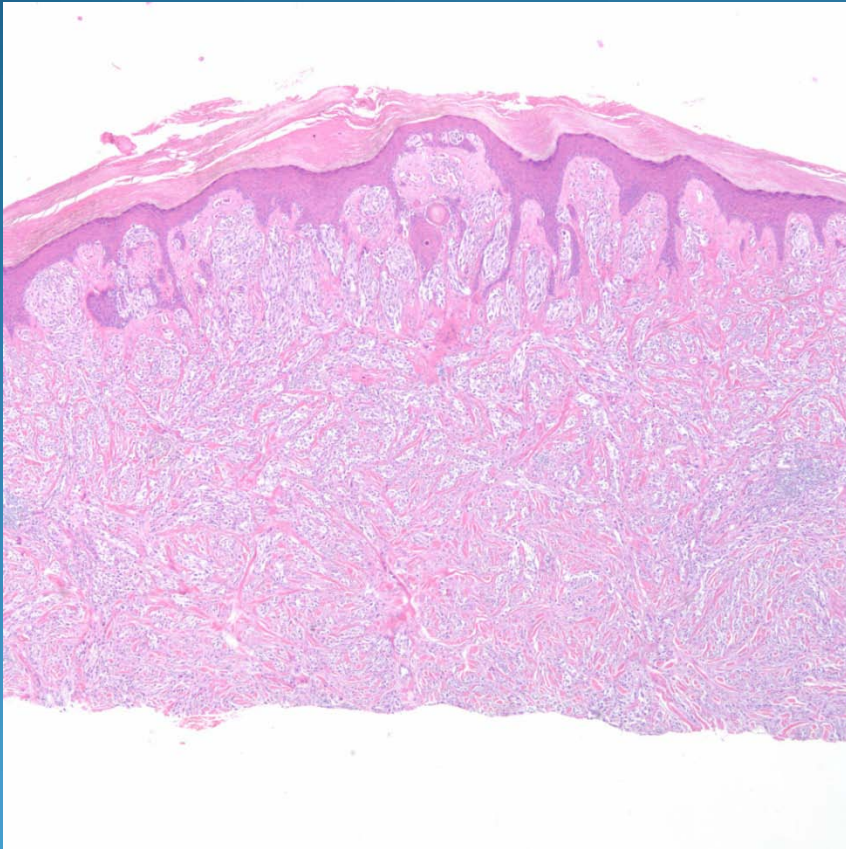


Melanoma with Spitzoid Features

Pearls



- Broad and asymmetrical melanocytic proliferation
- Epithelioid and spindled melanocytes
- No maturation and solid cohesive growth to base
- Look for mitotic figures in base of lesion